

PennHIP Report

Referring Veterinarian: Dr Zoran Djordjevich	Clinic Name: Mohnacky Animal Hospital of Carlsbad
Email: carlsbad@mohnackyyvet.com	Clinic Address: 2505 S. Vista Way Carlsbad, CA 92008
	Phone: (760) 729-3330
	Fax: (760) 729-2536

Patient Information

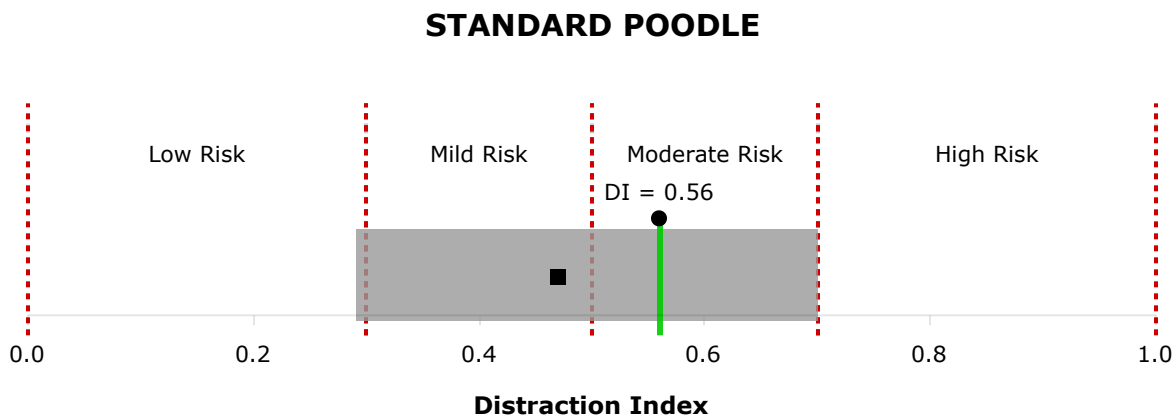
Client: de lisle, ashley	Tattoo Num:
Patient Name: jax	Patient ID: c152232
Reg. Name:	Registration Num:
PennHIP Num: 159532	Microchip Num:
Species: Canine	Breed: STANDARD POODLE
Date of Birth: 30 Jan 2021	Age: 20 weeks
Sex: Male	Weight: 37 lbs/16.8 kgs
Date of Study: 22 Jun 2021	Date Submitted: 08 Jul 2021
Date of Report: 08 Jul 2021	

Findings

Distraction Index (DI): Right DI = 0.56, Left DI = 0.48.
 Osteoarthritis (OA): **No radiographic evidence of OA for either hip.**
 Cavitation/Other Findings: No cavitation present.

Interpretation

Distraction Index (DI): The laxity ranking is based on the hip with the greater laxity (larger DI). In this case the DI used is 0.56.
 OA Risk Category: The DI is between 0.50 and 0.69. This patient is at moderate risk for hip OA.
 Distraction Index Chart:



BREED STATISTICS: This interpretation is based on a cross-section of 4601 canine patients of the STANDARD POODLE breed in the AIS PennHIP database. The gray strip represents the central 90% range of DIs (0.29 - 0.70) for the breed. The breed average DI is 0.47 (solid square). The patient DI is the solid circle (0.56).

SUMMARY: The degree of laxity (DI = 0.56) falls within the central 90% range of DIs for the breed. This amount of hip laxity places the hip at a moderate risk to develop hip OA. **No radiographic evidence of OA for either hip.**