

AIS PennHIP

(877) 727-6800 www.antechimagingervices.com

Doctor's Copy

PennHIP Report

Referring Veterinarian: Dr Zoran Djordjevich	Clinic Name: Mohnacky Animal Hospital of Carlsbad
Email: carlsbad@mohnackyyvet.com	Clinic Address: 2505 S. Vista Way Carlsbad, CA 92008
	Phone: (760) 729-3330
	Fax: (760) 729-2536

Patient Information

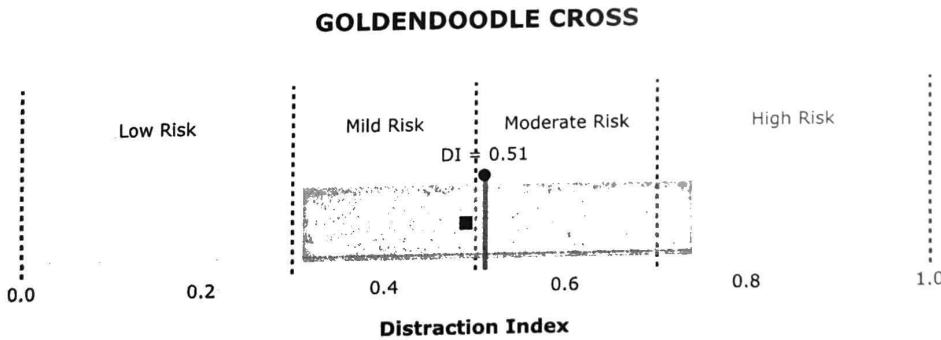
Client: De Isle, Ashley	Tattoo Num:
Patient Name: Duke	Patient ID: 154787
Reg. Name:	Registration Num:
PennHIP Num: 164289	Microchip Num:
Species: Canine	Breed: GOLDDOODLE CROSS
Date of Birth: 11 Jun 2021	Age: 19 weeks
Sex: Male	Weight: 29.4 lbs/13.3 kgs
Date of Study: 27 Oct 2021	Date Submitted: 01 Nov 2021
Date of Report: 05 Nov 2021	

Findings

Distraction Index (DI): Right DI = 0.50, Left DI = 0.51.
 Osteoarthritis (OA): **No radiographic evidence of OA for either hip.**
 Cavitation/Other Findings: No cavitation present.

Interpretation

Distraction Index (DI): The laxity ranking is based on the hip with the greater laxity (larger DI). In this case the DI used is 0.51.
 OA Risk Category: The DI is between 0.50 and 0.69. This patient is at moderate risk for hip OA.
 Distraction Index Chart:



BREED STATISTICS: This interpretation is based on a cross-section of 2325 canine patients of the GOLDENDOODLE CROSS breed in the AIS PennHIP database. The gray strip represents the central 90% range of DIs (0.31 - 0.74) for the breed. The breed average DI is 0.49 (solid square). The patient DI is the solid circle (0.51).

SUMMARY: The degree of laxity (DI = 0.51) falls within the central 90% range of DIs for the breed. This amount of hip laxity places the hip at a moderate risk to develop hip OA. **No radiographic evidence of OA for either hip.**

INTERPRETATION AND RECOMMENDATIONS: No OA/Moderate Risk: Likely to develop radiographic evidence of hip OA by 1-10 years of age (70% of dogs.) The risk to develop OA, the timing of OA onset, and the rate of progression are dependent upon many factors including DI, breed, body weight, age, and activity levels.
Recommendations: Evidence-based strategies to lower the risk of dogs getting OA or to treat those having OA fall into 5 modalities.* For detailed information, consult these documents.* Use any or all of these modalities as needed:
 1) For acute or chronic pain prescribe NSAID PO short or long term. Amantadine can be added if response is marginal or if

neuropathic pain is suspected.

2) Optimize body weight, keep lean, at BCS = 5/9.

3) Prescribe therapeutic exercise at intensities that do not precipitate lameness.

4) Administer polysulfated glycosaminoglycans IM or SQ, so-called DMOAD.

5) Feed an EPA-rich prescription diet preventatively for dogs at risk for OA or therapeutically for dogs already showing radiographic signs of OA.

At the present time there is inadequate evidence to confidently recommend any of the many other remedies to prevent or treat OA. Studies are in progress. Consider repeating radiographs at periodic intervals to determine the rate of OA progression and adjust treatment accordingly. Older dogs may show clinical signs such as chronic pain, reluctance to go stairs or jump onto the bed, and stiffness particularly after resting. It is unlikely that end-stage hip disease will develop for dogs at this risk level so surgical therapy for the pain of hip OA would rarely be indicated.

Breeding Recommendations: Please consult the PennHIP Manual.

* From WSAVA Global Pain Council Guidelines and the 2015 AAHA/AAFP Pain Management Guidelines

COMMENTS:

The femurs were too extended on the Distraction view. They should be angled slightly forward. An imaginary line (or the transverse collimator line) drawn between the tibial tuberosities should cross the cranial pubis. Another guideline for femoral positioning is to view the dog from the side: the tibial tuberosities should be vertical to the greater trochanters. See the PennHIP Manual for a full description of proper positioning.

Caudally directed (extended) femur positioning predisposes to cavitation. No cavitation was noted in this case.

Thank you for your attention to this in the future.